

the Clinical Chemist

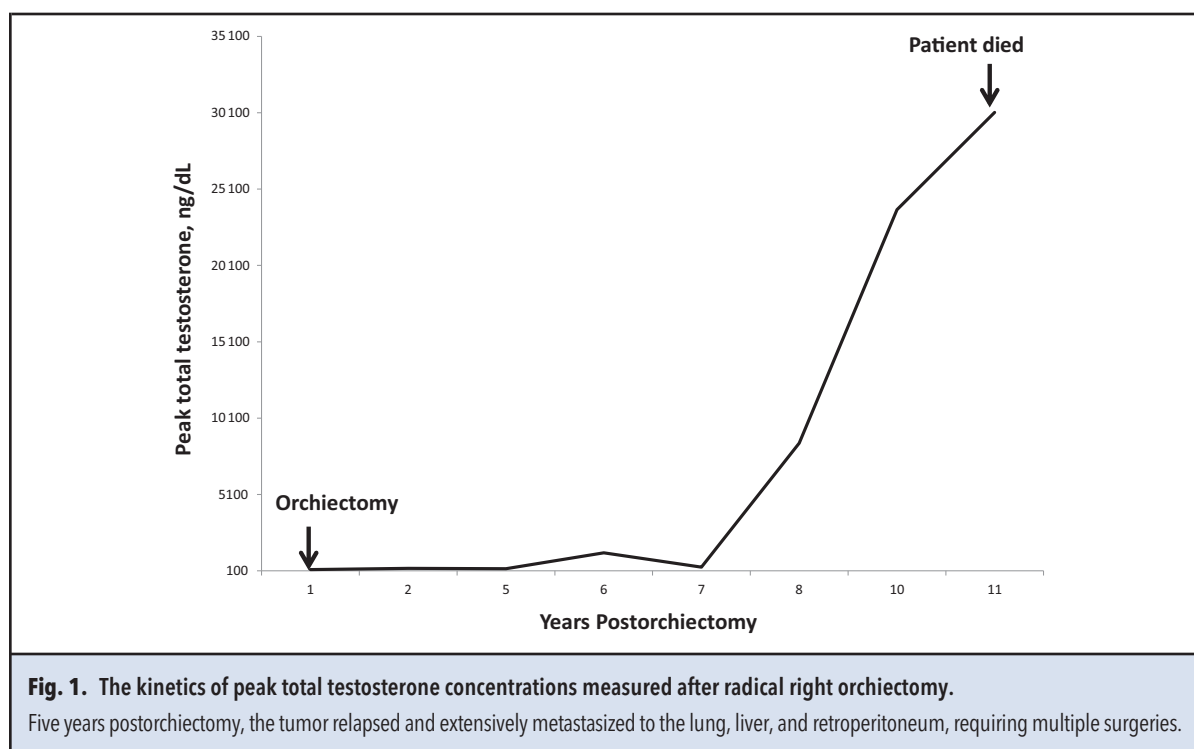
What Is Your Guess?

Highest Testosterone Concentration Ever: Pathology or Laboratory Error?

Merih T. Tesfazghi^{1*} and Christopher W. Farnsworth²

CASE DESCRIPTION

The laboratory obtained a testosterone result of 30 117 ng/dL for a 51-year-old man and called the medical director to assess whether this value was feasible because it would represent the highest testosterone concentration ever reported by the laboratory. The patient was an avid runner with a history of a right testicular mass and orchiectomy 10 years previously. The patient was supplemented with testosterone cypionate (200 mg/2 weeks). The results for follicle-stimulating hormone and luteinizing hormone were unremarkable.



¹ Rush University Medical Center, Chicago, IL; ² Washington University in St. Louis, St. Louis, MO.

* Address correspondence to this author at: Department of Pathology, Rush University Medical Center, 1750 W Harrison St, Chicago, IL 60612. Fax 314-362-1461; e-mail merih_tesfazghi@rush.edu.

Received April 28, 2018; accepted May 14, 2018.
© 2018 American Association for Clinical Chemistry
DOI: 10.1373/clinchem.2018.291468

QUESTIONS

1. What conditions are associated with the extremely high testosterone concentrations?
2. Could exogenous testosterone account for this concentration?
3. If pathological, what is the prognosis for patients with this condition?

The answers are below.

ANSWER

Increased testosterone concentrations are seen in individuals with exogenous testosterone supplements and sex hormone-producing adrenal tumors. At supraphysiological doses, exogenous supplements could raise serum testosterone concentrations by approximately 2- to 6-fold (1–3). This patient had a metastatic Leydig cell tumor diagnosed 5 years postorchietomy. Testosterone concentrations began to increase dramatically around this time (Fig. 1). Malignant Leydig cell tumor is refractory to chemotherapy and radiotherapy (4). The median survival time of patients with malignant Leydig cell tumor is 2 years (5).

Author Contributions: All authors confirmed they have contributed to the intellectual content of this paper and have met the following 4 requirements: (a) significant contributions to the conception and design, acquisition of data, or analysis and interpretation of data; (b) drafting or revising the article for intellectual content; (c) final approval of the published article; and (d) agreement to be accountable for all aspects of the article thus

ensuring that questions related to the accuracy or integrity of any part of the article are appropriately investigated and resolved.

Authors' Disclosures or Potential Conflicts of Interest: No authors declared any potential conflicts of interest.

References

1. Bhasin S, Woodhouse L, Casaburi R, Singh AB, Bhasin D, Berman N, et al. Testosterone dose-response relationships in healthy young men. *Am J Physiol Endocrinol Metab* 2001;281:E1172–81.
2. Bhasin S, Storer TW, Berman N, Callegari C, Clevenger B, Phillips J, et al. The effects of supraphysiologic doses of testosterone on muscle size and strength in normal men. *N Engl J Med* 1996;335:1–7.
3. Pope HG Jr, Kouri EM, Hudson JI. Effects of supraphysiologic doses of testosterone on mood and aggression in normal men: a randomized controlled trial. *Arch Gen Psychiatry* 2000;57:133–40, discussion 55–6.
4. Idrees MT, Ulbright TM, Oliva E, Young RH, Montironi R, Egevad L, et al. The World Health Organization 2016 classification of testicular non-germ cell tumours: a review and update from the International Society of Urological Pathology testis consultation panel. *Histopathology* 2017;70:513–21.
5. Al-Agha OM, Axiotis CA. An in-depth look at Leydig cell tumor of the testis. *Arch Pathol Lab Med* 2007;131:311–7.