

Surgical Techniques

Subcutaneous Testosterone Pellet Implantation Procedure for Treatment of Testosterone Deficiency Syndrome

Richard K. Cavender, MD

68 North High, New Albany, OH, USA

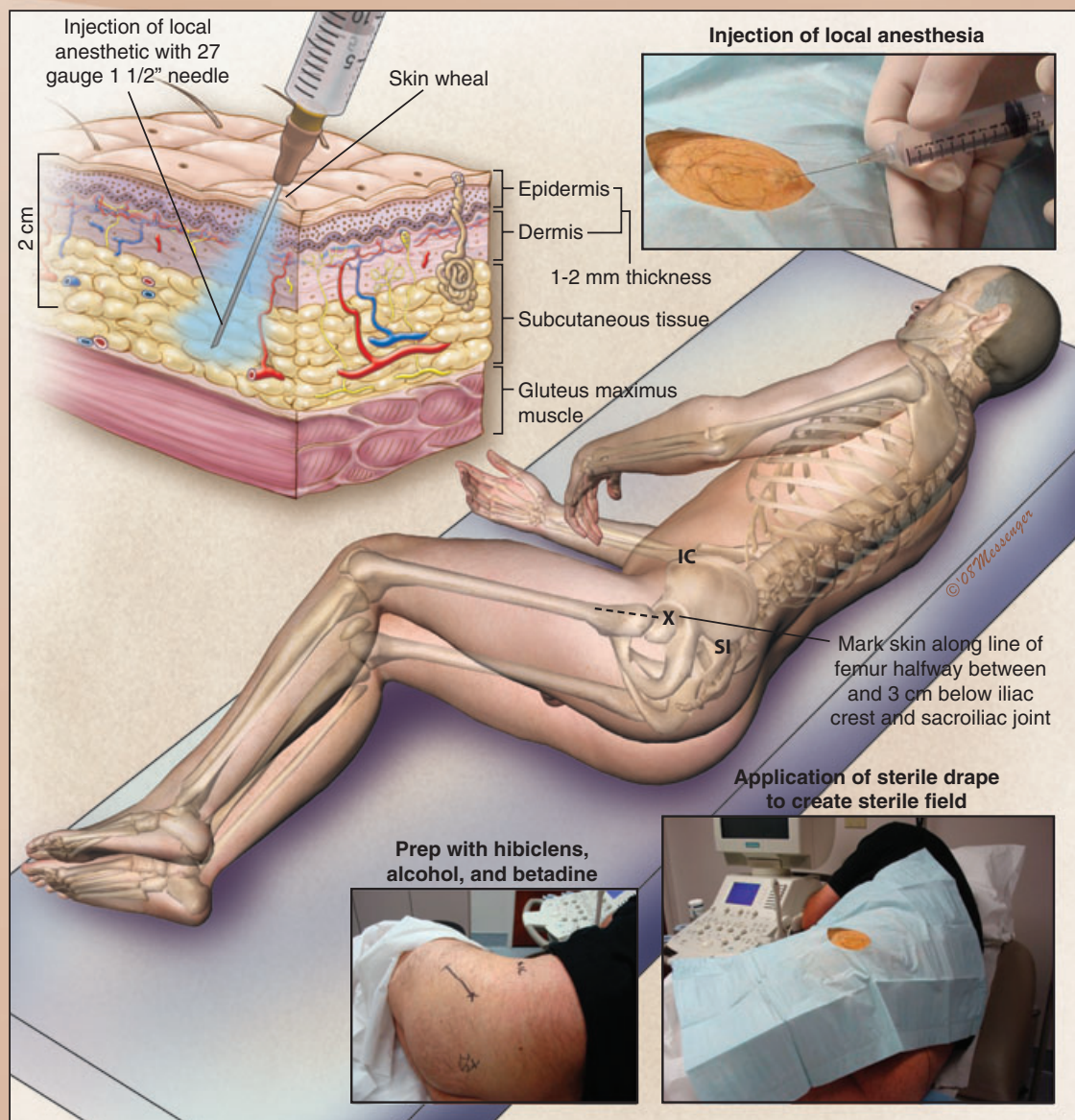


FIGURE 1

The patient is placed in the lateral jackknife or fetal position. Implantation occurs in the upper outer quadrant of the posterior gluteal region. The skin is marked 3 cm below the halfway mark between the iliac crest and sacroiliac joint in a 10-cm line parallel to the femur. Hibiclens, alcohol and povidone-iodine solution are used sequentially to prep. A sterile skin drape is used. For local vasoconstriction, 2% lidocaine (10 mL) with epinephrine (1:100,000) is administered first by skin wheal and then to a depth 2 cm below the skin using a 1.5-inch 25–27 gauge needle. Repeated subcutaneous injection results in a large fan-shaped anesthetized area.

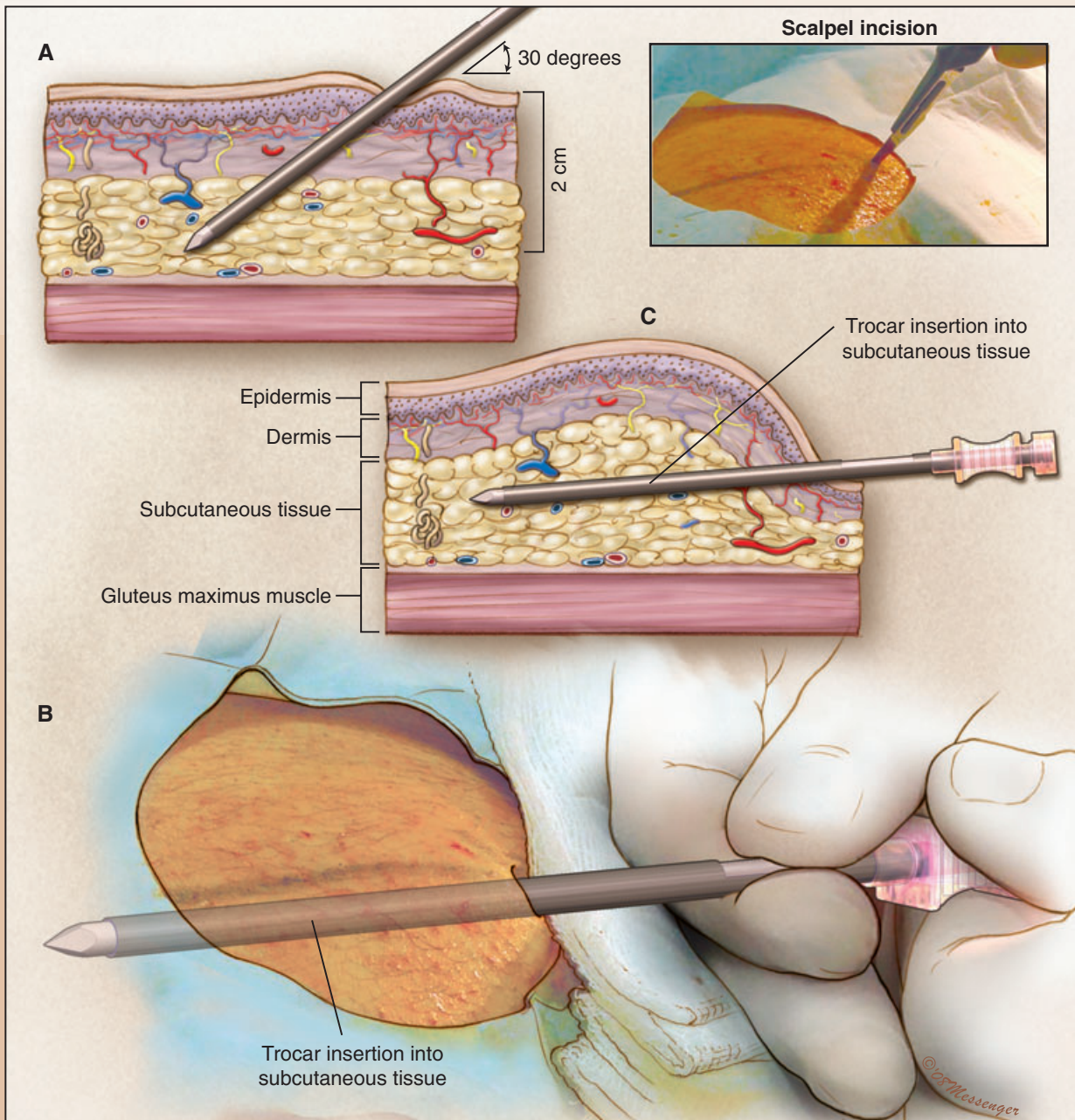


FIGURE 2

Following adequate local anesthesia, a #11 blade scalpel is used to make a 4-mm stab incision. The trocar with stylet is then introduced at a 30-degree angle to the skin surface and then advanced to a depth of 2 cm within the subcutaneous tissue. The trocar and stylet are then angled horizontally to the skin surface and advanced in the trajectory of the femur at a 2 cm depth. The trocar and stylet are advanced until reaching the trocar slot where the testosterone pellets will be placed. The stylet is then removed.

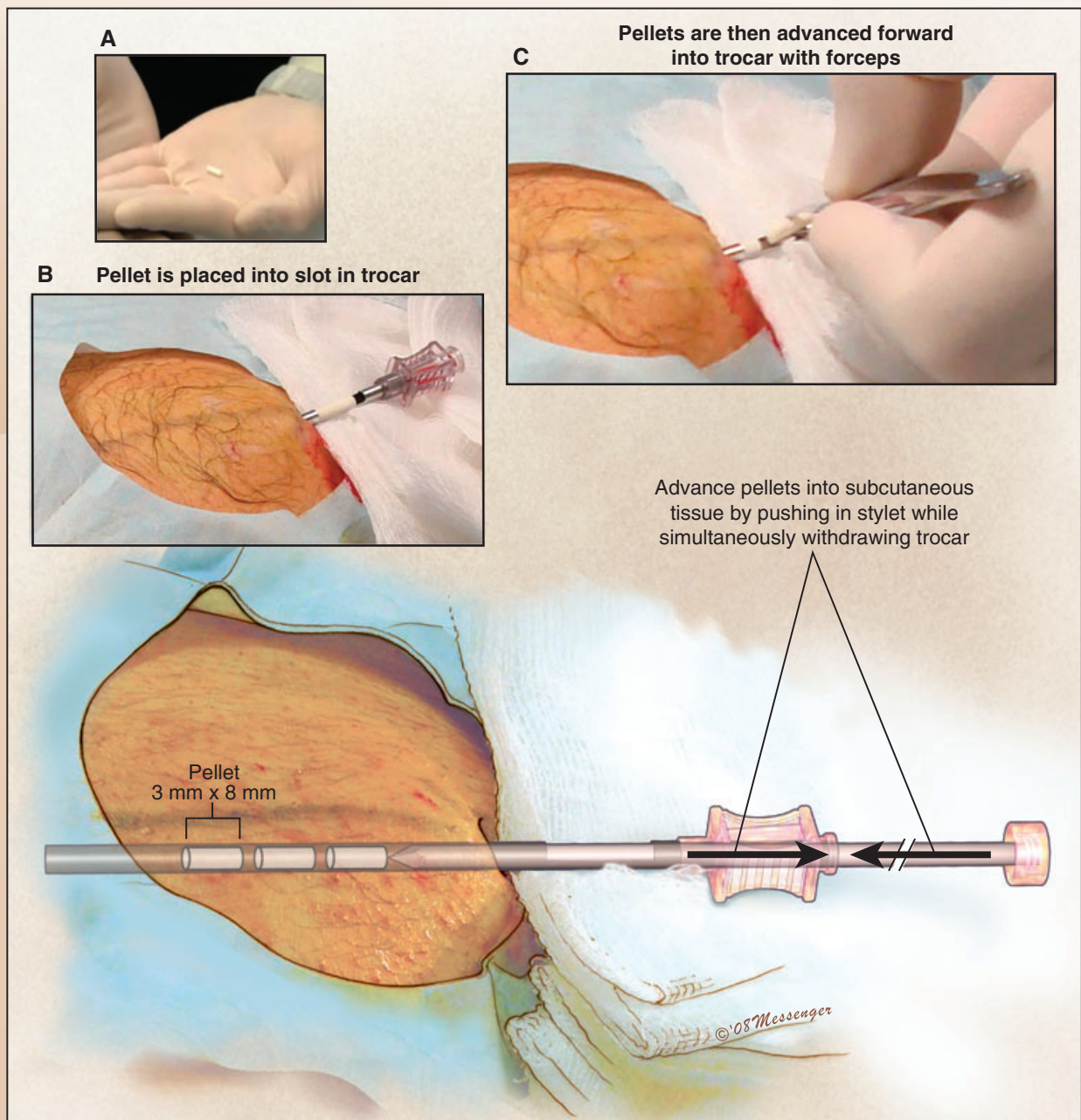


FIGURE 3

The testosterone implants are carefully placed into the trocar slot. Each pellet is advanced within the hollow trocar sheath. One strategy is to insert a pellet subcutaneously one at a time. The stylet is advanced inward within the trocar as the trocar is slowly withdrawn. Lateral movement of the trocar can release the pellet 90 degrees to the trocar tract. A second strategy is to insert all the pellets subcutaneously at one time. After all the pellets have been inserted into the hollow trocar sheath, the stylet is advanced inward within the trocar as the trocar is slowly withdrawn.

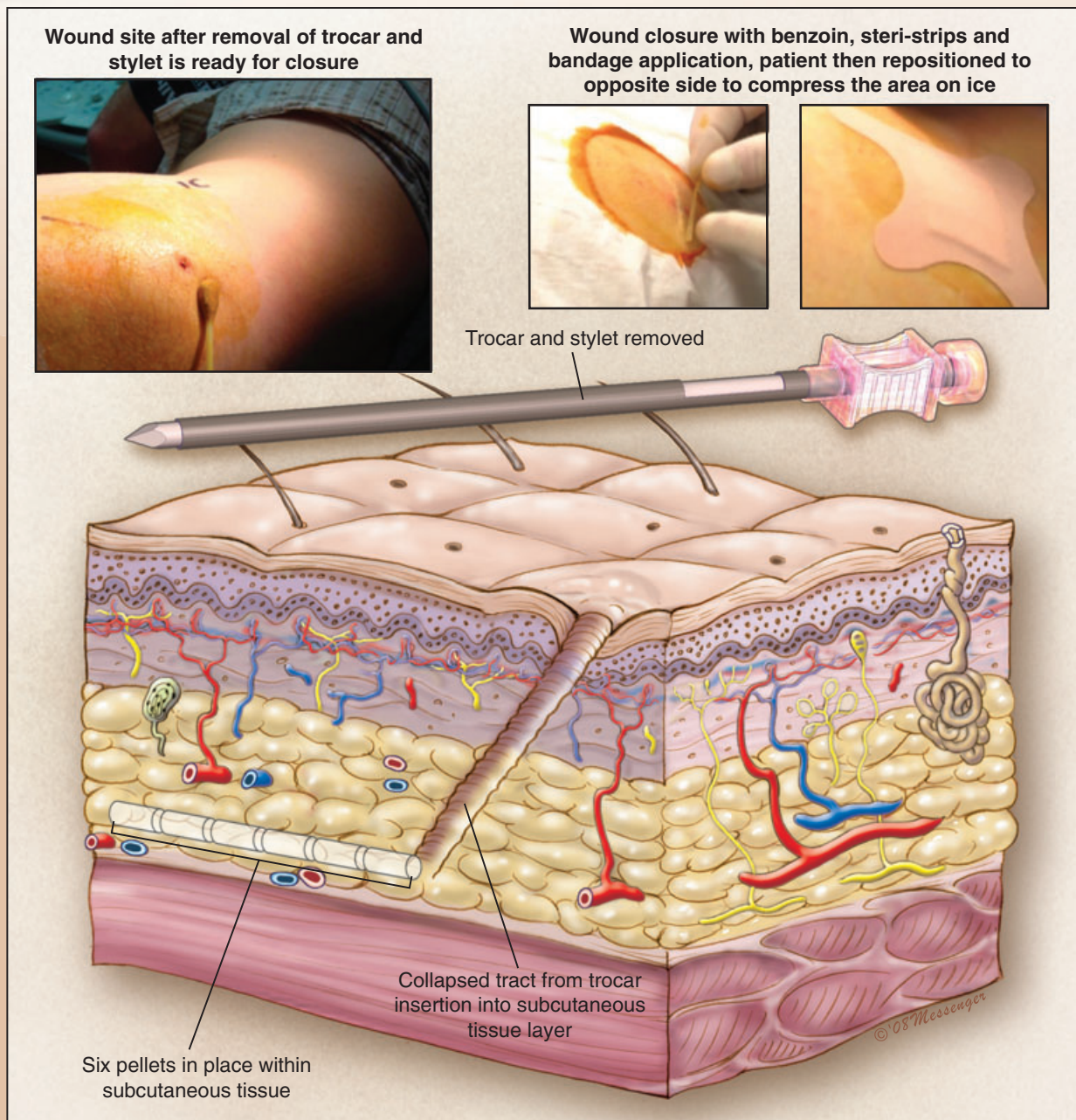


FIGURE 4

After all pellets are placed and the trocar has been removed, tincture of benzoin is placed on the skin. Steri-strips are then used to close the skin and a sterile bandage is placed to protect the area. The patient is then placed in the opposite position and the implant site is subjected to cold compression by utilizing body weight on an ice pack for approximately 10 minutes.