



Research Paper

The contribution of the *in-vivo* fate of an oil depot to drug absorptionR.W. Kalicharan^{a,b,*}, C. Oussoren^b, P. Schot^c, E. de Rijk^d, H. Vromans^{a,b}^a Department of Clinical Pharmacy, Division of Laboratory & Pharmacy, University Medical Center Utrecht, P/O Box 85500, 3508 GA Utrecht, the Netherlands^b Department of Pharmaceutics, UIPS, Utrecht University, PO Box 80082, 3508 TB Utrecht, The Netherlands^c OrgaNext Research BV, Jansbuitensingel 7, 6811 AA Arnhem, The Netherlands^d Charles River Laboratories, P/O Box 3476, 5203 DL, Den Bosch, The Netherlands

ARTICLE INFO

Article history:

Received 25 February 2017

Received in revised form 14 June 2017

Accepted 15 June 2017

Available online 17 June 2017

Keywords:

Oil depot

Surface area

Spatial volume

Depot disappearance

Intramuscular

Subcutaneous

Rats

ABSTRACT

Sustained release of lipophilic compounds can be achieved with oil depots. These parenteral formulations are generally injected in the vastus lateralis and deltoid muscle. It is known that the absorption rate differs between these two muscles. The reason for this is not fully understood. The aim of the current study was to investigate the fate of an oil depot in different tissues to elucidate whether the disappearance rate of oil is the cause of observed differences in absorption rate.

A study with healthy volunteers was conducted to determine 1.0 mL oil depots in the vastus lateralis and deltoid muscle for two weeks. The spatial distribution of the oil depots was determined using MRI. Additionally, a study in rats was conducted to microscopically examine the oil immediately and after 31 days of injection. All rats were injected with a 0.1 mL oil depot with and without benzyl alcohol (BOH), a commonly used excipient in oil depots.

In humans, it was shown that all oil depots were equal in volume and surface area directly after injection. Moreover, the disappearance rate for all oil depots was similar; within one week there was no depot visible anymore by MRI. This in contrast to the depots in rats, which were still microscopically visible after 31 days. It is concluded from these observations that the oil is dispersed to small droplets in the course of time. The resulting increase in surface area does not lead to an increase in absorption rate however.

The results of this paper show that the variation in drug absorption as found for the two muscles is not caused by a distinction in surface areas or disappearance rates of the oil depots. Therefore, it is argued that the local tissue drainage (e.g. lymph flow) plays a considerable role in drug absorption from oil depots, whereby the lymph flow differs between the muscles.

© 2017 The Authors. Published by Elsevier B.V. This is an open access article under the CC BY-NC-ND license (<http://creativecommons.org/licenses/by-nc-nd/4.0/>).

1. Introduction

Long-term drug treatment is optimised using sustained delivery of drugs. This is applied for a number of diseases, such as hormone-related (Edelstein and Basaria, 2010; Morgentaler et al., 2008) and psychiatric disorders (Covell et al., 2012; Novakovic et al., 2013; Uchida et al., 2013; van Weringh et al., 1994). This method of drug delivery can be achieved with the use of parenteral oil formulations. Long-acting parenteral injections are

administered intramuscularly (i.m.) or subcutaneously (s.c.) (Prettyman, 2005).

A considerable number of oil depots is registered for clinical use. These formulations are composed out of lipophilic compounds, dissolved in vegetable oils (arachis, sesame or castor oil). A commonly used additive is benzyl alcohol (BOH), which enhances the solubility of the lipophilic compound in the oil, decreases the oil viscosity to ease the administration and provides some local anaesthesia. Examples of oil depots registered on the market contain nandrolone decanoate (ND) (Bagchus et al., 2005; Minto et al., 1997; Wijnand et al., 1985), testosterone undecanoate (Morgentaler et al., 2008), estradiol valerate (Düsterberg and Nishino, 1982) or haloperidol decanoate (van Weringh et al., 1994). In all cases, the drug substance is compounded as a lipophilic prodrug. These oil depots are administered only once every 2–3 weeks.

* Corresponding author at: Department of Clinical Pharmacy, Division of Laboratory & Pharmacy, University Medical Center Utrecht, P/O Box 85500, 3508 GA, Utrecht, The Netherlands.

E-mail address: r.kalicharan@umcutrecht.nl (R.W. Kalicharan).

In the recent years, new insights into the fundamental mechanisms of drug absorption from an oil depot have been obtained (Kalicharan et al., 2016c). Here, it is necessary to distinct the drug release out of the oil depot and the absorption into the systemic circulation. After injection of the oil depot, the inactive prodrug (e.g. nandrolone decanoate) is released into the aqueous phase (*interstitial fluid*). This drug release is described by mass transport models, in which the release is determined by the drug partition coefficient ($\log P$), the concentration gradient between the oil and aqueous phase and the surface area of the oil depot. It has been assumed by Shaffer et al. that an injected oil depot forms a spherical shape in muscle tissue (Shaffer, 1929). In theory, a 0.5 mL injected oil depot would result in a spherical object with a surface area of 304.6 mm². In our previous study we showed with MRI that the *in situ* surface area of a 0.5 mL administered oil depot is approximately 750 mm² (Kalicharan et al., 2016a). This measured surface area is much larger due to the spatial distribution of the oil liquid throughout the muscle fibers. Obviously, the shape was definitely not spherical, but stretched.

Once released from the oil depot, the prodrug must be hydrolysed into its active (parent) compound to become therapeutically active. It is generally known that hydrolysis of prodrugs with an ester bond can occur via chemical or enzymatic routes. Recently, it was concluded that carboxylesterases are responsible for the fast conversion of the prodrug (Kalicharan et al., 2016b). It was shown that prodrug hydrolysis occurs in human whole blood, but it is absent in human plasma and serum. Since the interstitial fluid has a similar composition as serum, hydrolysis at the injection site is not expected to occur either. Surrounding tissue cells contain the appropriate esterases, but because of the poor tissue permeation, the lipophilic compound cannot reach these local enzymes. Therefore, it was argued that the inactive prodrug is drained via the lymphatic system to the systemic circulation where it can be hydrolysed into the parent compound (Kalicharan et al., 2016b, 2016c). The experiments indicated that the carboxylesterases are located in blood cells. It was shown that the prodrug hydrolysis did not start immediately, but after a delay of approximately half an hour, the time needed for permeation into the cells. The total time delay between the moment of injection and the appearance of the active substance in the systemic circulation (overall lag time) is a result of lymph transport and permeation into blood cells.

The rate at which the drug substance enters the blood stream is determined by the factors that have been described; The so-called *absorption rate constant* (k_a) was found to be mainly determined by the partition coefficient of the prodrug and the site of injection (Kalicharan et al., 2016c). The three mentioned absorption

variables (lag time, k_a and site of injection) are summarized in Fig. 1 for ND. It has been shown that there is a correlation between the *lag time* and k_a for nandrolone after injection in three different muscles (Kalicharan et al., 2016c). The explanation for the differences in kinetic parameters is still lacking. Fig. 1 also shows that a ND oil depot administered in the subcutaneous tissue results in a low nandrolone absorption rate constant and a relatively short lag time.

Although the mechanism of drug absorption from an oil depot has become somewhat more clear, there are still some phenomena that should be studied. First of all, the oil depot formulations and volumes in Fig. 1 were equal for the i.m. injection, and therefore, it is likely that the different k_a 's are caused by factors within the body. For example, the shape and hence the surface area of the oil depot may differ. Also, although it is still unknown how rapidly the oil depot (with the prodrug) disappears from different muscles after injection, it is possible that the disappearance rate of the oil differs between these muscles. In this respect it should be noted that there were some remarkable results in the previous study in which the spatial distribution of an administered oil depot was determined: a significant variation in oil depot disappearance rate was noticed (Kalicharan et al., 2016a). The period in which the oil depot seemed to disappear from the biceps branchii varied between 2 and 14 days. Until now, all pharmacokinetic studies on oil depots show at least 2 weeks of sustained levels of the active substance (Bagchus et al., 2005; Jann et al., 1985; Minto et al., 1997; van Weringh et al., 1994; Wijnand et al., 1985), indicating that the functionality of sustained drug release is maintained during this period.

In this current study, the surface areas and disappearance rates of oil depots injected in the vastus lateralis and deltoid muscle were determined *in situ* using MRI. Although this technique was suitable to visualize oil in tissue, there is a possibility that it exhibits a too low sensitivity to detect oil that is spread out in the tissue (Kalicharan et al., 2016a). Therefore, this paper covers also a histology study in rats to determine whether the oil is still present in tissue after some prolonged time. Histological studies of human and rat muscles show a similar structure of tissue (Armstrong et al., 1983; Fridén et al., 1981) and it can therefore be assumed that the observations in rats have significance for human tissue.

The aim of the current study was to investigate the fate of an oil depot in different tissues in order to elucidate whether the disappearance rate of oil is the cause of observed differences in absorption rate. Both the MRI and histology study should provide some clarity in the rate of absorption of active substances from oil depots.

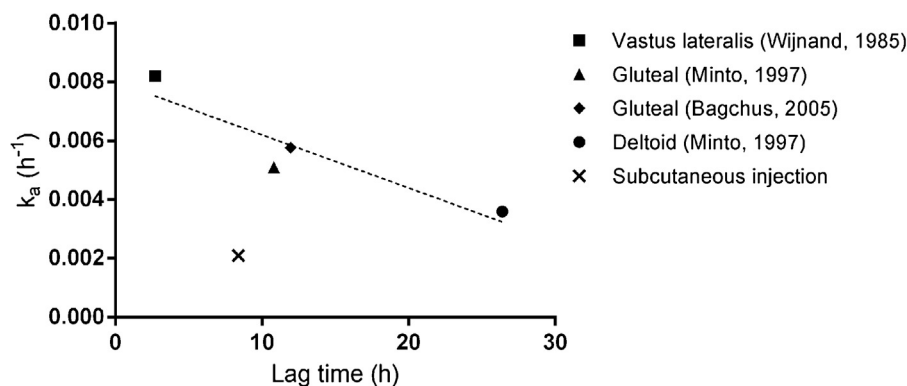


Fig. 1. obtained from (Kalicharan et al., 2016d). Plot of absorption rate constant (k_a) and lag time of nandrolone administered at different injection sites: deltoid (●), gluteal (◆ and ▲), vastus lateralis (■) muscle and subcutaneous tissue (x). All i.m. injections were 1 mL at a concentration of 233 $\mu\text{mol/mL}$ nandrolone decanoate. The s.c. injection (0.5 mL) had a concentration of 117 $\mu\text{mol/mL}$ nandrolone decanoate.

2. Materials and methods

2.1. Chemical substances

Benzyl alcohol (BOH) (Ph. Eur.) and sesame oil (Ph. Eur.) were purchased from Fagron NL BV (Capelle aan den IJssel, the Netherlands).

2.2. Oil depots

Oil depots contained sesame oil mixed with 10% (m/v) benzyl alcohol. The formulation was sterilised by filtration (0.2 mm, Mini Kleenpak Fluorodyne II, Pall Corporation, USA) and packed under current Good Manufacturing Practice conditions in the Clinical Pharmacy University Medical Center Utrecht, the Netherlands.

2.3. MRI study

2.3.1. Volunteers

Four healthy male volunteers participated in the study. The characteristics of the volunteers are summarized in Table 1. Ethical approval for the study was obtained from the ethical committee of the University Medical Center Utrecht, the Netherlands (protocol number: 14–401/D). Written informed consent according to the latest Declaration of Helsinki was obtained from all volunteers. Inclusion criteria were: healthy males with an age between 18 and 65 years old. Exclusion criteria: claustrophobic, metal clips or wires in the upper arm or thigh, implanted pacemakers, allergies to sesame oil or benzyl alcohol, other depots present in the same muscle or smoking.

2.3.2. Magnetic resonance imaging

A clinical 1.5-T MRI-scanner (Achieva, Philips Healthcare, Best, the Netherlands) was used to perform the imaging studies. The MRI scan parameters and methods used in the current study are described elsewhere (Kalicharan et al., 2016a).

2.3.3. Study design

Each volunteer received one 1.0 mL injection in both the left deltoid and left vastus lateralis muscle. Before each injection, two separate planning (blank) scans were made with MRI by positioning the surface coil on the muscle of interest. These scans were used to determine the injection location in the specific muscle of the oil depot. Subsequently, 1.0 mL oil depot was injected with a 21G needle in each muscle directly after each other. MRI scans of the injections sites in both muscles were made immediately after injection and 1, 2, 3, 6, 8, 10 and 13 days after injection. The scanning of the injection site was stopped if the oil depot could not be detected on two consecutive scan days.

2.4. Data processing

The oil depot volume and surface area were determined using the procedure as described previously (Kalicharan et al., 2016a). All data is depicted as mean \pm SD. An unpaired *t*-test was conducted to compare the properties of the oil depots injected in the vastus lateralis and deltoid muscle. A *P*-value less than 0.05 was

considered as significantly different. All data and statistical analysis were performed in GraphPad Prism version 6.02.

2.5. Histological study

18 male Wistar rats (CrI:WI(Han); Charles River Deutschland, Sulzfeld, Germany) were used in the current study. All rats were approximately 5 weeks old and weighed at least 120 g. Subcutaneous (group 1 and 2) and intramuscular (group 3) injections were administered using a 25G needle.

All rats were injected once on day 1 and once on day 31 with 0.1 mL oil depot. The vehiculum of the oil depot differed per study group, as given in Table 2. Each study group consisted of six rats. All rats of group 1 and 2 were subcutaneously injected at the left caudal side of the back (day 1) and at the left cranial side of the back (day 31). All rats of group 3 were intramuscularly injected at the left hind leg (lateral) (day 1) and at the left hind leg (medial) (day 31).

Rats were sacrificed on day 32, where after all injection sites (including from day 1) and gross lesions in the skin were evaluated to assess local irritation of the test substances. All injection sites were collected from all animals at necropsy and fixed in 10% buffered formalin (neutral phosphate buffered 4% formaldehyde solution, Klinipath, Duiven, the Netherlands). Sections were cut at a thickness of 2–4 μ m and stained with hematoxylin and eosin and evaluated using a light microscope.

3. Results and discussion

This study reports the *in situ* surface area and disappearance rate of an oil depot injected in the deltoid and vastus lateralis muscle in human male volunteers using MRI. In addition, the oil depot is characterized in rat muscle and subcutaneous tissue via histopathology.

3.1. MRI

Healthy male volunteers (*n*=4) were included in the current study (Table 1). All oil depots were injected between 10 and 20 mm deep. Unfortunately, in one volunteer, the oil depot appeared to have leaked from the deltoid directly after injection. In retrospect, this oil depot was injected insufficiently deep (10 mm). No adverse events were reported during the complete study duration.

The *in situ* volume and surface area of the oil depots (mean (\pm SD)) were significantly equal in the deltoid and vastus lateralis directly after injection (Table 3). The shape of the oil depots in this (Table 4) and in our previous study (Kalicharan et al., 2016a) is flat and sheet-like. It is assumed that the oil spreads across multiple fascicles to form a continuous phase in both muscles.

Although the spatial distribution of the oil depot is similar in all muscles, the disappearance rates of the oil seems to differ. During the successive 6 days, all oil depots in this study disappeared completely from their injection site (Fig. 2). In our previously reported study (Study 1 in Fig. 2) there were however two oil depots still visible for more than 10 days. The differences between the two studies are the injected volumes and injection sites: in the current study a 1.0 mL oil depot was injected in deltoid and vastus

Table 1
Volunteer baseline characteristics (*n* = 4).

	Mean \pm SD
Age (years)	28.5 \pm 4.5
Length (meters)	1.8 \pm 0.1
Weight (kilograms)	76.8 \pm 9.0
BMI (kg/m ²)	23.7 \pm 1.3

Table 2
Study design of rat study.

Group	Percentage of BOH	Route of administration
1	0	s.c.
2	10	s.c.
3	10	i.m.

Abbreviations: BOH = benzyl alcohol; s.c. = subcutaneous; i.m. = intramuscular.

Table 3
Overview of injected oil depots in each muscle. Volume and surface area are measured directly after injection.

	Deltoid (n = 3)	Vastus lateralis (n = 4)	P ^a
Volume (mm ³)	891.7 ± 87.7	999.5 ± 66.1	0.1563
Surface (mm ²)	1163.7 ± 164.5	1693.7 ± 407.1	0.0753

Data is shown as mean ± SD.
^a comparison between deltoid and vastus lateralis.

lateralis, whereas in the previous study biceps branchii was provided with a 0.5 mL oil depot. In both studies, the procedure of drug administration, type of needle and nursing personnel were comparable. Although a larger amount of oil seems in general to disappear quicker, there was also one 0.5 mL oil depot that disappeared within 2 days in the previous study (▼). Interestingly, one participant (■) was included in both studies: in the previous study, the oil depot could be detected for 14 days, while in the current study both oil depots disappeared within 6 days. These combined MRI results show that the speed at which an oil depot disappears from the injection site is highly variable, both inter- and intra-individually.

As earlier indicated, we have previously shown that the release characteristics of a ND oil depot differed between the muscles (Fig. 1). The current study shows that this cannot be explained by the results obtained with MRI (Fig. 2). Furthermore, there seems to be a discrepancy between the oil disappearance rate and the

exposure of the active substances in clinical studies. Two independent clinical studies with 1.0 mL ND oil depots showed that the nandrolone levels persisted for about three weeks (Minto et al., 1997; Wijnand et al., 1985). It should be noted in this respect that the oil determination by MRI is based on voxels with a certain resolution. The measurements in this study had a detection limit of 0.05 mL oil (= 8 voxels of 1 × 1 × 1 mm) (Kalicharan et al., 2016a). As already suggested in our previous paper, it is possible that the injected oil depot is still present at the injection site but may not be visible by MRI. For this reason, histological studies were conducted to further investigate the fate of oil *in situ*.

3.2. Histological studies

No mortality was seen during the study period. There were no relevant test-substance related clinical signs after the first injection (day 1). After the second injection (day 31), mild clinical signs in all subcutaneously injected rats consisted of scabs and/or swelling at the flanks. These were not seen in the intramuscularly injected rats.

The subcutaneously and intramuscularly injected samples showed the presence of vacuoles (Fig. 3). These vacuoles were morphologically characterized as clear, round to oval spaces, surrounded by a thin layer of some inflammatory cells. It is likely that these vacuoles represent the injection fluid, which was washed out during the histology sample preparation process. As

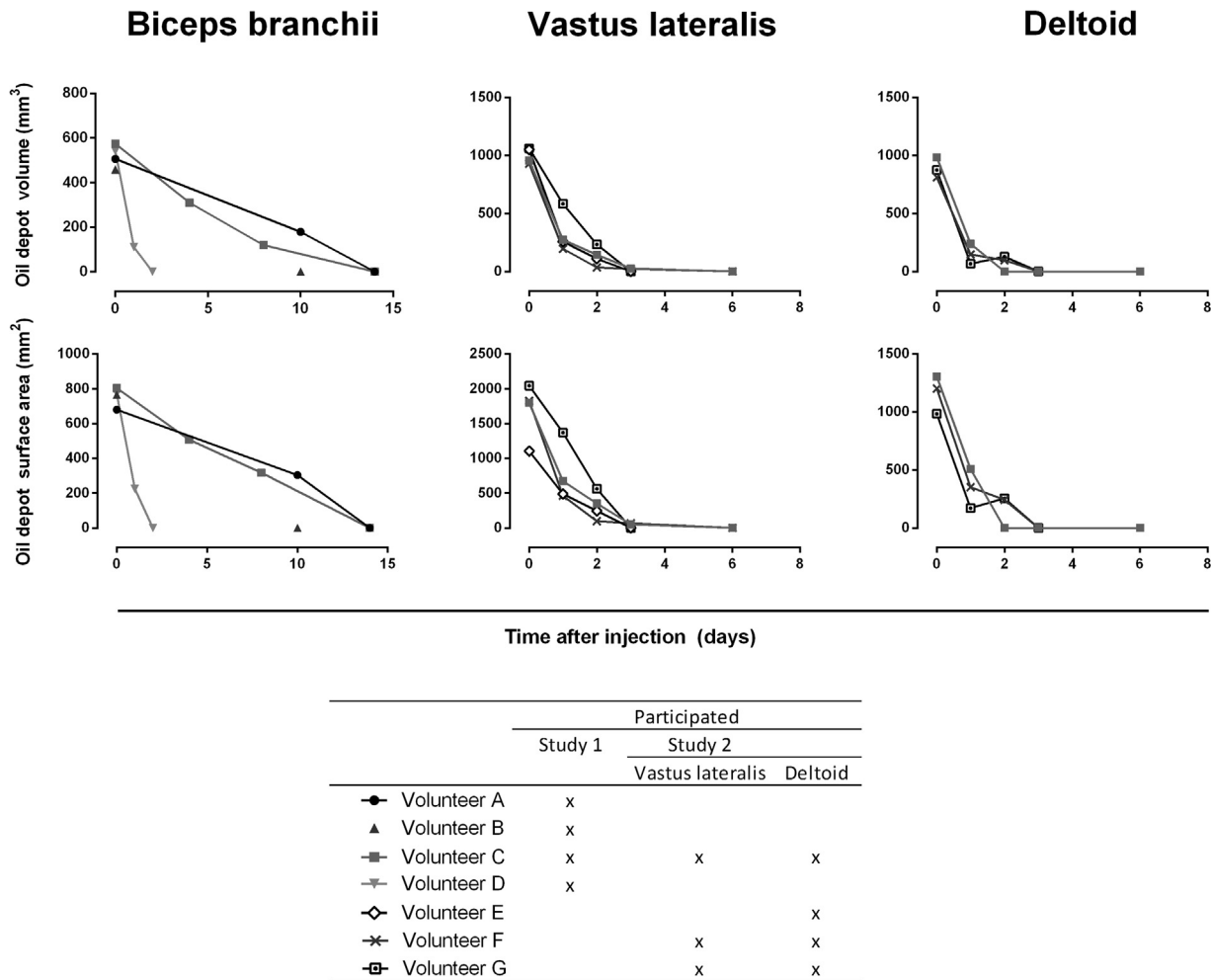


Fig. 2. Time course of oil depot volumes and surface areas after injection in the biceps branchii (0.5 mL; data from previous study (Kalicharan et al., 2016a)), the vastus lateralis and the deltoid muscle (both 1.0 mL).

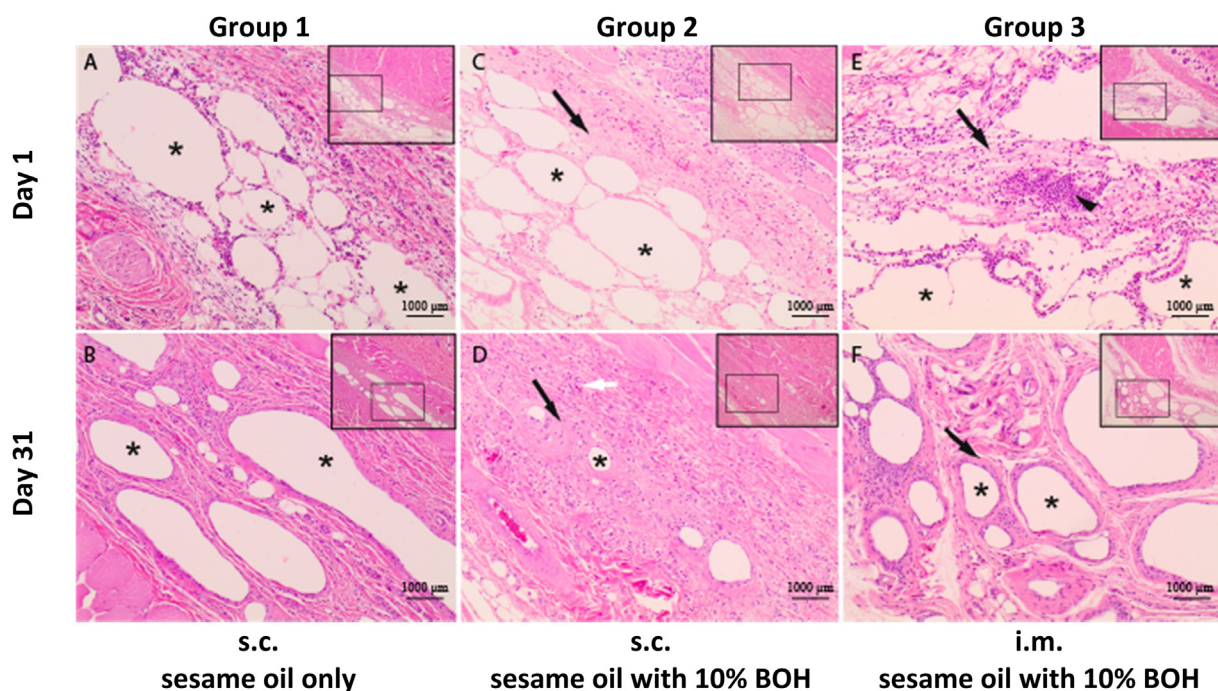


Fig. 3. Histopathology of the rat subcutaneous (A–D) and intramuscular (E and F) injection sites at day 1 and 31. Representation of the oil is indicated with asterisks (*). Black arrows show the collagen formation (C–F). Neovascularization is seen in group 2 after 31 days (see white arrow in figure D).

can be seen in Fig. 3, the oil is not a distinct continuous phase but represents several separate droplets. This is already noticeable after 1 day. The microscopical resolution in the histopathology study is much higher than that of the MRI, as can be seen in this figure where scale bars show a length of 1000 μm . When a fine dispersion of droplets develops, it is most probably not measured anymore by MRI. As has been illustrated in the previous study by alteration of the cut-off value intensity, the MRI measurement revealed that more oil could be present than detected (Kalicharan et al., 2016a). This indicates in fact that a MRI-scanner with a higher resolution is needed to determine smaller fractions oil accurately. The disappearance of the oil from the injection as seen in Fig. 2 is therefore an apparent disappearance, as the fine droplets may still be present at the injection site. The oil depot is still microscopically visible after 31 days. Combining the results from both approaches, it can be concluded that the oil depot does not represent a discrete, continuous phase but is dispersed into separate droplets. This occurs already in the first few days. Clearly, the oil is still present after a month, albeit that it may consist of a dispersion of small droplets.

3.3. Mechanisms of drug absorption

The fact that the oil is obviously still present in the tissue explains the continuing exposure of the active substance. However, an interesting aspect of the formation of small droplets is an increase in surface area. Mass transfer models state that the surface area of the oil depot is relevant for the release rate of the compound. An increased surface area should then lead to a higher release. This implies that a larger injected volume of oil results in a higher release rate of dissolved compounds due to the larger surface area of the depot. The obvious explanation for this is that the surface area of the separate droplets is apparently of minor importance. In this respect, it can be argued that the drug release rate is determined by the outer-layer of the assembly of droplets, encapsulated at the injection site (as seen in Fig. 3F); Consequently, the droplets in the centre of the fragmented oil depot have minor contribution to the drug release rate.

The current study shows that there is no reason to assume that differences in spatial distribution of the oil (Table 3) are responsible for the rate of absorption or lag time that have been

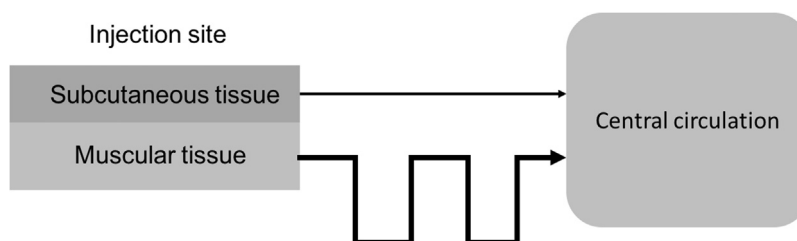
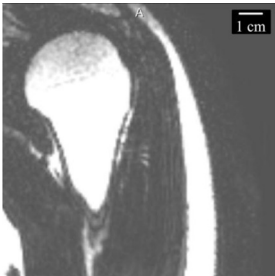
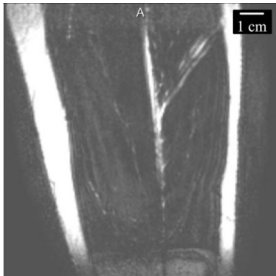
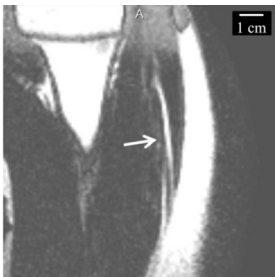

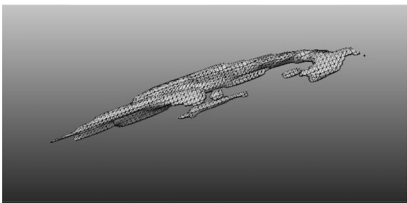
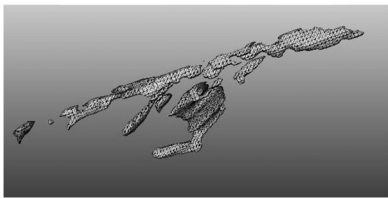


Fig. 4. Schematic overview of suggested drug transport paths from the subcutaneous and muscular tissue to the central circulation. Drug transport from the subcutaneous tissue will occur at a low flow rate and via a relative short path length, whereas the drug transport from muscular tissues will occur at a higher flow, but via a longer path length.

Table 4
Visualisation of the oil depot in the deltoid and vastus lateralis muscle of volunteer C. The images of the planning scan (first row with images) show no oil depot. White arrows indicate the oil depot in tissue (second row with images). The 3D-picture of the oil depot is given in the third row with images.

Volunteer C		
	Deltoid	Vastus lateralis
Planning scan		
Direct after injection	2D 	
	3D 	

found for the tissues (Fig. 1). Therefore, it must be concluded that the cause must be found elsewhere in the body. Several body parameters have been suggested to be relevant during drug absorption (Prettyman, 2005; Zuidema et al., 1994, 1988): type of tissue, blood and lymph flow in tissues, physical activity of the tissue and the local activation of the immune system.

Recently, Darville et al. reported that the immune system is activated after parenteral administration (Darville et al., 2016). It is generally known that the immune system is triggered by foreign material. This might be the mechanism of oil disappearance after injection. And although not studied by us, it is very likely that this activation is related to the amount of foreign material. This could be the reason why the larger amount (1.0 mL) of administered oil in this study disappears earlier than the lower amount (0.5 mL) of oil in the previous study (see Fig. 2).

Fig. 1 shows that not only the drug absorption rate constant and lag time between i.m. injected oil depots differ, but also the subcutaneous from the intramuscular injection. It has already been argued that drug absorption of lipophilic prodrugs starts with uptake via the lymphatic system. Subsequently, once transported through the lymphatic system, the prodrug enters the *vena cava superior* and the systemic circulation. Here, it is hydrolysed. With the findings of the current study, we conclude that the cause of

absorption variables cannot be found in the fate of the oil after injection. At the same time, once in the systemic circulation, there is no difference either. This means that the cause must be found in between. Therefore, the difference in drug absorption rate constant and lag time from s.c. or i.m. injected oil depots can be explained by different absorption path lengths via lymph flows and tissue specific lymphatic vessel lengths.

The lower nandrolone k_a after a s.c. injection as shown in Fig. 1 is then due to a lower drainage flow from the subcutaneous tissue towards lymph nodes (Stanton et al., 2009). Stanton et al. showed that ^{99m}Tc - human IgG (a radiolabelled macromolecule) was almost twice as fast cleared from muscle tissue compared to s.c. tissue. This implies that subcutaneous and intramuscular tissue have separate afferent lymph vessels.

The shorter nandrolone lag time after a s.c. injection (Fig. 1) must then be due to a combination of local activation of the immune system (e.g. macrophages) and a shorter path length towards the systemic circulation: Drug absorption from s.c. administered oil depots appears earlier in time (shorter lag time), but at a lower velocity (lower k_a). This in contrast to drug absorption from i.m. injected oil depots from the same organ, where drugs appear after a longer period (longer lag time), but at a higher velocity (higher k_a). Fig. 4 depicts an illustration of this

concept. This makes sense from an evolutionary perspective, because leukocytes take the shortest way to eliminate exogenous material after infection in the skin.

4. Conclusion

In this paper, the rate of disappearance of oil depots from the vastus lateralis and deltoid muscle is similar. The scanning method with MRI is only sufficient to determine the parameters of interest on the same injection day. After one day of injection, histological studies in rats showed that the oil is dispersed and that a part of the oil remains at the site of injection for 31 days. This was not seen with MRI analysis. It is concluded that differences in drug absorption cannot be explained by drug product properties such as the surface areas or mentioned disappearance rates of oil depots. Therefore, body factors such as the activated immune system can influence this with macrophages. Speculatively, the lymph flow and path length at the injection site is argued to be the dominating factor in drug absorption of the released compounds from oil depots.

Funding

This research did not receive any specific grant from funding agencies in the public, commercial, or not-for-profit sectors.

References

- Armstrong, R.B., Ogilvie, R.W., Schwane, J.A., 1983. Eccentric exercise-induced injury to rat skeletal muscle. *J. Appl. Physiol. Environ. Exerc. Physiol.* 54, 80–93.
- Bagchus, W.M., Smeets, J.M.W., Verheul, H.A.M., De Jager-Van Der Veen, S.M., Port, A., Geurts, T.B.P., 2005. Pharmacokinetic evaluation of three different intramuscular doses of nandrolone decanoate: analysis of serum and urine samples in healthy men. *J. Clin. Endocrinol. Metab.* 90, 2624–2630. doi:http://dx.doi.org/10.1210/jc.2004-1526.
- Covell, N.H., McEvoy, J.P., Schooler, N.R., Stroup, T.S., Jackson, C.T., Rojas, I.A., Essock, S.M., 2012. Effectiveness of switching from long-acting injectable fluphenazine or haloperidol decanoate to long-acting injectable risperidone microspheres. *J. Clin. Psychiatry* 73, 669–675. doi:http://dx.doi.org/10.4088/JCP.11m07074.
- Düsterberg, B., Nishino, Y., 1982. Pharmacokinetic and pharmacological features of oestradiol valerate. *Maturitas* 4, 315–324.
- Darville, N., Van Heerden, M., Mariën, D., De Meulder, M., Rossenu, S., Vermeulen, A., Vynckier, A., De Jonghe, S., Sterkens, P., Annaert, P., Van Den Mooter, G., 2016. The effect of macrophage and angiogenesis inhibition on the drug release and absorption from an intramuscular sustained-release paliperidone palmitate suspension. *J. Control. Release* 230, 95–108. doi:http://dx.doi.org/10.1016/j.jconrel.2016.03.041.
- Edelstein, D., Basaria, S., 2010. Testosterone undecanoate in the treatment of male hypogonadism. *Expert Opin. Pharmacother.* 11, 2095–2106. doi:http://dx.doi.org/10.1517/14656566.2010.505920.
- Fridén, J., Sjöström, M., Ekblom, B., 1981. A morphological study of delayed muscle soreness. *Experientia* 37, 506–507. doi:http://dx.doi.org/10.1007/BF01986165.
- Jann, M.W., Ereshefsky, L., Saklad, S.R., 1985. Clinical pharmacokinetics of the depot antipsychotics. *Clin. Pharmacokinet.* 10, 315–333. doi:http://dx.doi.org/10.2165/00003088-198510040-00003.
- Kalicharan, R.W., Baron, P., Oussoren, C., Bartels, L.W., Vromans, H., 2016a. Spatial distribution of oil depots monitored in human muscle using MRI. *Int. J. Pharm.* 505, 52–60. doi:http://dx.doi.org/10.1016/j.ijpharm.2016.03.064.
- Kalicharan, R.W., Bout, M.R., Oussoren, C., Vromans, H., 2016b. Where does hydrolysis of nandrolone decanoate occur in the human body after release from an oil depot? *Int. J. Pharm.* 515, 721–728. doi:http://dx.doi.org/10.1016/j.ijpharm.2016.10.068.
- Kalicharan, R.W., Schot, P., Vromans, H., 2016c. Fundamental understanding of drug absorption from a parenteral oil depot. *Eur. J. Pharm. Sci.* 83, 19–27. doi:http://dx.doi.org/10.1016/j.ejps.2015.12.011.
- Minto, C., Howe, C., Wishart, S., Conway, A., Handelsman, D., 1997. Pharmacokinetics and pharmacodynamics of nandrolone esters in oil vehicle: effects of ester, injection site and injection volume. *J. Pharmacol. Exp. Ther.* 281, 93–102.
- Morgentaler, A., Dobs, A.S., Kaufman, J.M., Miner, M.M., Shabsigh, R., Swerdloff, R.S., Wang, C., 2008. Long acting testosterone undecanoate therapy in men with hypogonadism: results of a pharmacokinetic clinical study. *J. Urol.* 180, 2307–2313. doi:http://dx.doi.org/10.1016/j.juro.2008.08.126.
- Novakovic, V., Adel, T., Peselow, E., Lindenmayer, J.-P., 2013. Long-Acting injectable antipsychotics and the development of postinjection Delirium/Sedation syndrome (PDSS). *Clin. Neuropharmacol.* 36, 59–62. doi:http://dx.doi.org/10.1097/WNF.0b013e3182854f70.
- Prettyman, J., 2005. Subcutaneous or intramuscular? Confronting a parenteral administration dilemma. *Medsurg Nurs.* 14, 93–99.
- Shaffer, L.W., 1929. The fate of intragluteal injections. *Arch. Dermatol.* 19, 347. doi:http://dx.doi.org/10.1001/archderm.1929.02380210002001.
- Stanton, A.W.B., Modi, S., Bennett Britton, T.M., Purushotham, A.D., Peters, A.M., Levick, J.R., Mortimer, P.S., 2009. Lymphatic drainage in the muscle and subcutis of the arm after breast cancer treatment. *Breast Cancer Res. Treat.* 117, 549–557. doi:http://dx.doi.org/10.1007/s10549-008-0259-z.
- Uchida, T., Suzuki, T., Sakurai, H., Tsutsumi, C., Den, R., Mimura, M., Uchida, H., 2013. Ten year outcomes of outpatients with schizophrenia on conventional depot antipsychotics. *Int. Clin. Psychopharmacol.* 28, 261–266. doi:http://dx.doi.org/10.1097/YIC.0b013e328363aa5a.
- van Wieringh, G., Komen, B.J., Thieme, R.E., van der Hoeven, R.T.M., Vos, T., 1994. Comparative bioavailability study of two haloperidol decanoate containing products. *Pharm. World Sci.* 16, 343–347. doi:http://dx.doi.org/10.1007/BF02178564.
- Wijnand, H.P., Bosch, A.M.G., Donker, C.W., 1985. Pharmacokinetic parameters of nandrolone (19-nortestosterone) after intramuscular administration of nandrolone decanoate (Deca-Durabolin(R)) to healthy volunteers. *Eur. J. Endocrinol.* 110, S19–S30. doi:http://dx.doi.org/10.1530/acta.0.109S00019.
- Zuidema, J., Kadir, F., Titulaer, H.A.C., Oussoren, C., 1994. Release and absorption rates of intramuscularly and subcutaneously injected pharmaceuticals (II). *Int. J. Pharm.* 105, 189–207. doi:http://dx.doi.org/10.1016/0378-5173(94)90103-1.
- Zuidema, J., Pieters, F.A.J.M., Duchateau, G.S.M.J.E., 1988. Release and absorption rate aspects of intramuscularly injected pharmaceuticals. *Int. J. Pharm.* 47, 1–12. doi:http://dx.doi.org/10.1016/0378-5173(88)90209-8.